



**PATIENT**

Romeo Bregam

**PRESENTING CLINICAL SIGNS**

History: Increased RR and RE. Tachycardia. Coughing. Possible grade 1/6 murmur. Cardiomegaly.

**SPECIES**

Canine

**ELECTROCARDIOGRAPHIC FINDINGS** \*Note: Single lead ECGs are evaluated as a rhythm strip. Morphology/MEA cannot be definitively commented on.

A single lead ECG is available; 50mm/s, 20mm/mV. The average heart rate is 180bpm (range 170-200bpm). P waves cannot be identified; however, a sinus origin is suspected. P for every QRS complex and vice versa. The P and QRS morphologies are positive. No ectopic beats, pauses or other dysrhythmias observed.

**BREED**

Bulldog

ECG diagnosis: Suspect normal sinus tachycardia.

**SEX**

Male Neutered

**ECHOCARDIOGRAM FINDINGS**

2D, m-mode, color flow and doppler imaging is available. Mild left ventricular dilation with increased sphericity. Decreased systolic function (PW > IVS). EPSS increased. Moderate to severe left atrial enlargement. The mitral valve appears mildly thickened, with no obvious prolapse into the left atrial lumen. No obvious mitral regurgitation secondary to annular stretch. The tricuspid valve appears normal in form and function. Mild right atrial and ventricular dilation. No obvious tricuspid regurgitation. The aortic valve is normal in morphology and mobility. No subvalvular ridge present; normal LVOT velocity. No aortic insufficiency. Normal pulmonic valve with no pulmonic insufficiency seen. No pericardial or pleural effusion noted. No obvious cardiac tumors.

**AGE**

9 years

**WEIGHT**

97lbs

**CARDIAC CHART**

**INTERPRETED BY**

Maggie Machen Lamy,  
DVM, DACVIM  
(Cardiology)

CANINE CARDIAC PARAMETERS	MR VMAX (m/s)	TR VMAX (m/s)	LA/AO (Boon method)	LA/AO (Heart Base; Swe)	FS (%)	EF (%)	EPSS (cm)
NORMAL PARAMETER	4.5-5.5	<2.7	1.3	<1.6	28-40	40-100	<0.6
PATIENT			NM	2.0	21	40	NM
CANINE CARDIAC PARAMETERS	HR (BPM)	AV VMAX (m/s)	PV MAX (m/s)	BODY WEIGHT (kg)	LA 2D short axis Base view (cm)	LVIDd Avg: 2D and m-mode short axis (cm)	LVIDs Avg: 2D and m-mode short axis (cm)
NORMAL PARAMETER	50-100	0.7-1.7	0.7-1.6	BELOW	BELOW	BELOW	BELOW
PATIENT	NM	0.7	0.8	44.0	4.8	5.6	5.6
*Normal chamber parameters expressed as a mean value (SD)							
<b>BODY WEIGHT DEPENDENT PARAMETERS</b>							
*Note: All measurements based upon multi-modal images and methods. An average value is reported.							
				3	1.27 (5.3)	2.46 (2.46)	1.36 (5.5)
				5	1.40 (4.5)	2.74 (5.2)	1.60 (4.7)
				10	1.50 (3.8)	3.27 (3.5)	2.06 (3.1)
				15	1.83 (2.0)	3.71 (2.4)	2.43 (2.1)
				20	2.02 (1.9)	4.14 (2.2)	2.80 (2.0)
				25	2.18 (2.4)	4.48 (2.9)	3.10 (2.5)
				30	2.33 (3.3)	4.83 (3.9)	3.39 (3.4)
				35	2.48 (4.3)	5.17 (5.0)	3.69 (4.5)
				40	2.62 (5.2)	5.48 (6.1)	3.96 (5.4)
				50	2.88 (7.1)	6.07 (8.3)	4.46 (7.4)

Adapted from June Boon, Veterinary Echocardiography, 1998  
Rishniw M and Hollis NE, J Vet Intern Med 2000; 14:429-435  
Hansson et al, Vet Rad and Ultrasound 2002  
Bonagura et al. Echocardiography: principles of interpretation, Vet Clin North Am 15:1177, 1995

**IMAGING PERFORMED BY**

Dana Alterman,  
RDCS, LVT

**HOSPITAL NAME**

Eubank Animal Clinic

**REFERRING VET**

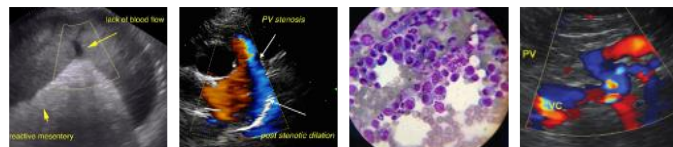
Dr. Martin

**INVOICE**

29267

**DATE**

2/27/23



**PATIENT**

Romeo Bregamn

**SPECIES**

Canine

**BREED**

Bulldog

**SEX**

Male Neutered

**AGE**

9 years

**WEIGHT**

97lbs

**INTERPRETED BY**

Maggie Machen Lamy,  
DVM, DACVIM  
(Cardiology)

**IMAGING PERFORMED BY**

Dana Alterman,  
RDCS, LVT

**HOSPITAL NAME**

Eubank Animal Clinic

**REFERRING VET**

Dr. Martin

**INVOICE**

29267

**DATE**

2/27/23

**INTERPRETATION OF THE FINDINGS & FURTHER RECOMMENDATIONS**

Unfortunately, this patient has evidence of myocardial failure. The LV function is moderately decreased (FS 18-22%), which is causing dilation and overload of all 4 chambers of the heart. No significant valve leaks are apparent; however, image quality is lacking in this signalment. No additional issues are identified; however, it is important to note that small abnormalities may have easily been missed. Additionally, the ECG simply shows tachycardia; however, due to device insensitivity further comment is difficult to make. My suspicion is this is sinus in origin and secondary to the current crisis; however, follow up is advised should tachycardia persist in the future.

Systolic failure can be primary in nature (DCM) or secondary to taurine deficiency, myocarditis, hypothyroidism, tachycardia-induced cardiomyopathy, or infiltrative disease such as lymphoma. In a senior bulldog, primary disease is likely; however, consider testing for primary causes that may be treatable. It is notable that the dysfunction is asymmetric (IVS appears to be moving normally), and may represent an infarcted region of the free wall. Going forward, a thyroid panel, cardiac troponin (cTnI) level and a taurine level can be considered. Diet should be evaluated in light of recent issues concerning grain free/boutique brand/exotic ingredient options. Finally, further systemic evaluation for underlying infiltrative contribution such as neoplasia is also reasonable (abdominal ultrasound, fluid cytology, etc.). Regardless of cause, prognosis is guarded long term with risk for complications going forward. The only treatable cause of systolic failure is taurine deficiency, which is uncommon on commercially formulated dog foods. If a taurine level is declined, it is also reasonable to simply supplement with taurine on the off chance of a malabsorption issue.

A cough in this patient should be approached carefully due to predisposition for primary respiratory disease. With moderate LA dilation, there may be early decompensation present. Screening CXR are highly recommended. Consider response to Lasix as well when determining if CHF was the cause. If the cough persists/worsens, hydrocodone and/or a course of Baytril should also be considered. Monitoring of sleeping breathing rates at home is recommended as the best way to screen for progression to CHF in the future.

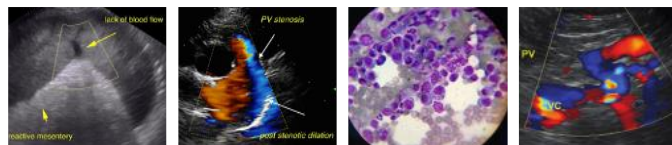
A screening BP is recommended. Cases of systolic failure are at high risk for malignant tachyarrhythmias (such as VT) and sudden death, and periodic ECG screenings are recommended.

Monitor for development of a progressive cough, labored breathing, exercise intolerance or collapse episodes in the future.

**PLAN:**

Recommend baseline blood pressure and CXR. Initiate aldosterone antagonist Spironolactone 1-2mg/kg PO q12h. Initiate pump support Pimobendan 0.2-.3mg/kg PO q12h. Once deemed normotensive (BP>130mmHg), initiate ACE-I Enalapril or Benazepril 0.5mg/kg PO q12h. Institute Lasix 1-2mg/kg PO q12h. Consider diet, thyroid status, etc. as discussed. If tachycardia persists despite therapy, reassess ECG (ideally a six-lead tracing).

A recheck echocardiogram is recommended in 6 months, sooner if any clinical signs arise.



**PATIENT**

Romeo Bregam

**SPECIES**

Canine

**BREED**

Bulldog

**SEX**

Male Neutered

**AGE**

9 years

**WEIGHT**

97lbs

**INTERPRETED BY**

Maggie Machen Lamy,  
DVM, DACVIM  
(Cardiology)

**IMAGING PERFORMED BY**

Dana Alterman,  
RDCS, LVT

**HOSPITAL NAME**

Eubank Animal Clinic

**REFERRING VET**

Dr. Martin

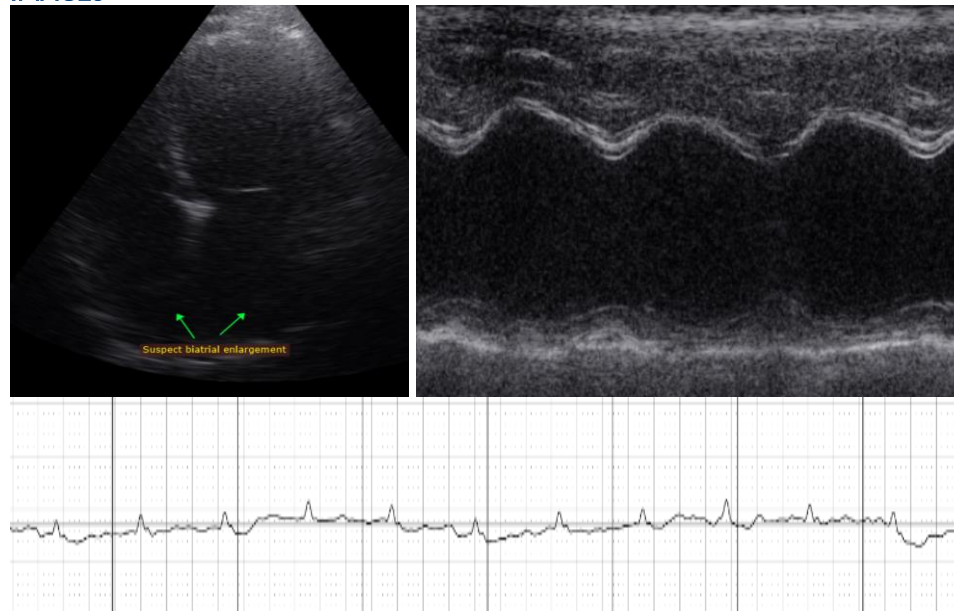
**INVOICE**

29267

**DATE**

2/27/23

**IMAGES**



The information and recommendations provided are based on the images presented by the referring veterinarian. No evaluation can be communicated regarding pathology that was not visible in the image/video clips provided.

Thank you for this referral. This report was generated using transcription software, and minor dictation errors may be present. If the clinical or image interpretation does not parallel your findings or if I can be of any further assistance, please contact me.

**Maggie Machen Lamy, DVM**  
Diplomate of the American College of Veterinary Internal Medicine (Cardiology)  
info@sonopath.com